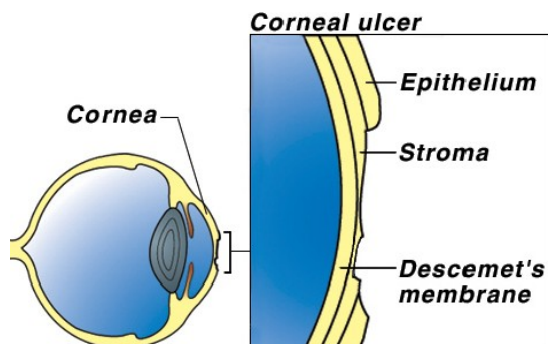


Corneal Ulcers in Cats

Author: Ernest Ward, DVM



The cornea is the clear, glistening membrane that makes up the surface of the eyeball. Think of it as a clear windowpane. To understand a corneal ulcer, you must first know how the cornea is constructed.

There are three layers in the cornea, all of which are highly specialized skin cells. The outermost layer is the *epithelium*, which is a very thin layer of cells (usually 5-6 rows thick). Below the epithelium is the *stroma*, which is the main supportive layer of the cornea, and the deepest layer is *Descemet's membrane*. Because all of these layers are clear,

it is not possible to see them without special stains that color specific cells and highlight them when the tissue is examined under a microscope.

A penetration or erosion through a few layers of the outermost corneal epithelium is called a *corneal erosion* or *corneal abrasion*. A *corneal ulcer* is an erosion through the entire epithelium down into the stroma. With a corneal ulcer, fluid is absorbed from the tears into the stroma, giving a cloudy appearance to the eye. If the ulcer goes through the stroma to the level of Descemet's membrane, a *descemetocoele* is formed. A descemetocoele is a very serious condition. If Descemet's membrane ruptures, the liquid inside the eyeball leaks out, the eye collapses and irreparable damage occurs.

What causes corneal ulcers?

There are several causes of corneal ulcers in cats. The most common cause is *trauma*. An ulcer may result from blunt trauma, such as a cat rubbing its eye against a rough surface, or due to a laceration, such as a cat-claw scratch or contact with a sharp object such as a thorn. The second most common cause is *chemical burn* of the cornea. This may happen when irritating shampoos, other liquids, chemicals or dust such as drywall dust gets in the eye.

"The most common cause is *trauma*."

Other causes of corneal ulcers include *bacterial infections*, *viral infections*, and other diseases. These conditions may originate in the eye or develop secondary to disease elsewhere in the body.

What are the clinical signs of corneal ulcers?

"A corneal ulcer is very painful."

A corneal ulcer is very painful. In response to this intense pain, most cats will rub the affected eye with a paw or on the carpet or furniture. To protect the eye, they will squint, blink rapidly or keep the lids tightly closed. Occasionally, a discharge will collect in the corner of the eye or run down the face.

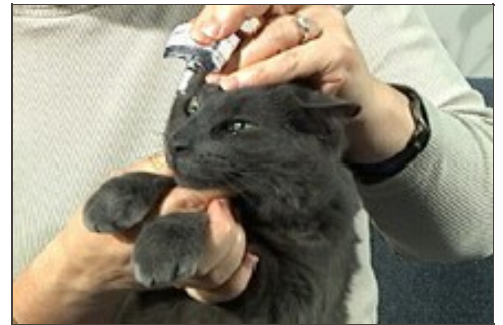How is a corneal ulcer diagnosed?

Superficial corneal abrasions are generally not visible without the aid of special equipment and stains. Corneal ulcers are usually detected with the use of *fluorescein stain*. A drop of this orange-colored stain is placed on the cornea. The dye will adhere to ulcerated areas and turn green. Large ulcers are easily seen, while tiny ulcers may be enhanced by the use of a special ophthalmic lights and filters. This is the most basic test performed and may be the only test needed if the ulcer is acute and very superficial. If the ulcer is chronic or is very deep, samples will be taken for culture and cell study *prior* to applying the stain or any other medication.

How is a corneal ulcer treated?

The form of treatment used depends on whether there is a corneal abrasion, corneal ulcer, or descemetocoele present.

Corneal abrasions generally heal within three to five days. Medication is used to prevent bacterial infections (antibiotic ophthalmic drops or ointment) and to relieve spasms or pain (atropine ophthalmic drops or ointment). Antibiotic drops are only effective for a short time (a few hours) so they must be applied frequently; ointments last a bit longer but still require application every few hours. For best results, the antibiotic preparation should be applied every four to six hours. On the other hand, the effects of atropine last many hours so this drug is only used every twelve to forty-eight hours.



If a deep **corneal ulcer** or a **descemetocoele** is present, steps must be taken to protect the eye and to promote healing. Since cats do not wear eye patches well, surgery may be required to protect the injury! Often, the surgeon will suture the third eyelid over the ulcer, or suture the eyelids together for a few days. In some cases, dead or dying cells may build up along the edges of the ulcer, preventing normal healing; if this occurs, surgical debridement and/or a grid keratectomy (removal of the dead and dying tissue) will be necessary so that healing can occur. Your veterinarian will choose the most appropriate surgical technique or combination of techniques for your cat.

Can a corneal abrasion progress to become an ulcer or a descemetocoele?

Yes. Veterinarians often prescribe broad-spectrum topical antibiotics for simple corneal abrasions or superficial ulcers. In spite of this treatment, the erosion or ulceration can sometimes continue or worsen. Since this can happen and could result in permanent loss of vision, your cat should be re-examined after two to three days of treatment, to be sure that healing is progressing properly. If healing is not progressing normally or if a complication develops, your veterinarian will recommend additional treatments or surgery.

Do any of the eye medications have side effects?

A cat will occasionally be sensitive to ophthalmic medication. If your cat seems to be in more pain after the medication is used, discontinue it and contact your veterinarian.

A cat with a corneal ulcer normally has significant eye discomfort, so it keeps the eyelids tightly closed. Atropine relieves the pain but also dilates the pupil widely. This means that the cat is very sensitive to light in that eye and may squint or hold the eye tightly closed when exposed to bright light. The dilation of the eyes may last for several days after the medication is stopped.

My cat began to drool excessively and paw at its mouth after I administered the eye medications. Is that a side effect?

Fluid drains from the eyes through the tear ducts, which empty into the back of the nose; some of this fluid can drain into the back of the mouth. Eye medications can drain through the tear ducts and end up in the mouth. Some eye medications have an unpleasant taste; atropine in particular has a very bitter taste. If it gets in the cat's mouth, either from running down the tear ducts or being licked off the paws, excessive and dramatic drooling may occur. This is not a drug reaction but a reaction to the terrible taste. The drooling will subside in a short time. However, once this happens, the cat may be more difficult to medicate in the future because it may anticipate the same thing happening again.

What else can I use to control the pain?

A topical anesthetic is often used to numb the cornea so diagnostic tests may be performed. However, these drugs are toxic to the corneal epithelium and prevent proper healing. They are safe for one time use, when used with caution. Atropine is commonly prescribed to treat the pain of a corneal ulcer. Some cats will benefit from the use of non-steroidal anti-inflammatory medications (NSAIDs). Your veterinarian will discuss this with you and determine if it is safe and appropriate for your pet's condition.

How do I know when the treatment is completed?

The best way to tell that the cornea has healed is to repeat the fluorescein stain test. This test will be performed by your veterinarian at intervals between one and seven days, depending on the severity of the condition and the progress of healing. NEVER discontinue treatment on your own.

What does it mean if there are red streaks near the ulcer?

There are no blood vessels in the normal cornea. However, when a corneal ulcer or descemetocoele occurs, the body will promote healing by forming a new blood supply across the surface of the cornea in a process called *neovascularization*. The new vessels begin at the sclera (the white part of the eye) and grow toward the ulcer.

Neovascularization will speed the healing of the ulcer. After the ulcer is healed, these vessels may remain in the cornea; if they are extensive, they will obstruct vision. The size of the blood vessels may be reduced by the application of a topical corticosteroid for a few days to several weeks, *after the ulcer has fully healed*. Corticosteroid-containing eye medications are NEVER used until an ulcer has completely healed because they will slow or stop the healing and may actually cause worsening of the ulcer. Your veterinarian will repeat the fluorescein dye test BEFORE prescribing any corticosteroid preparation.

If corticosteroids are used and pain occurs in the eye again, discontinue the steroids and have the eye rechecked immediately.

© Copyright 2009 Lifelearn Inc. Used and/or modified with permission under license.